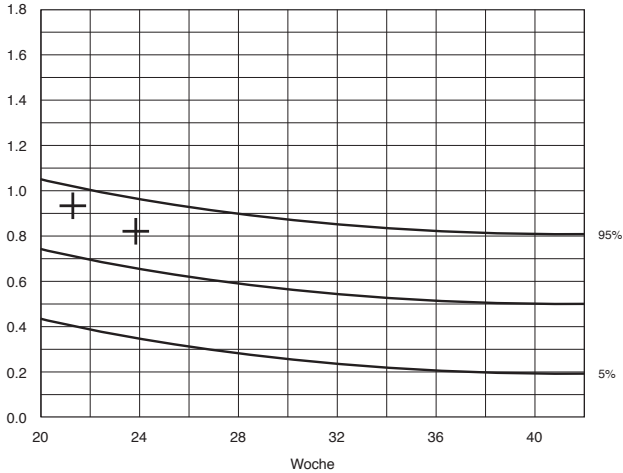
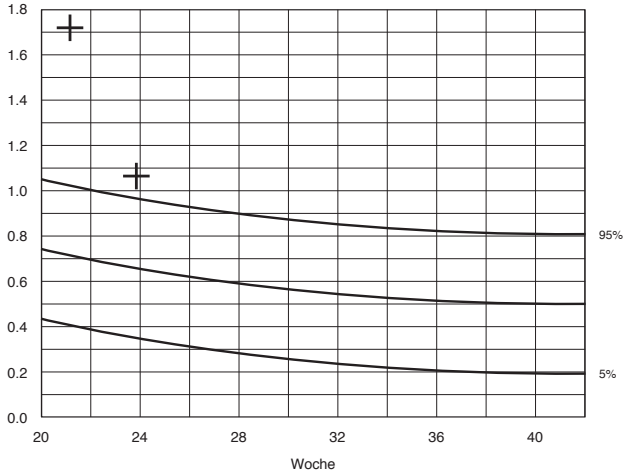


Dopplersonografie-Normwertkurven

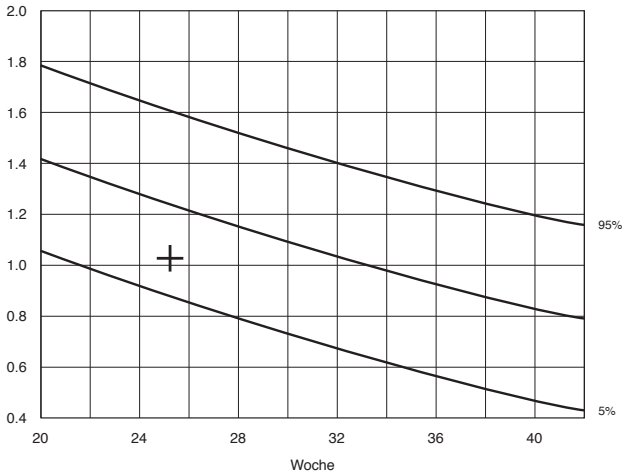
PI A. uterina rechts



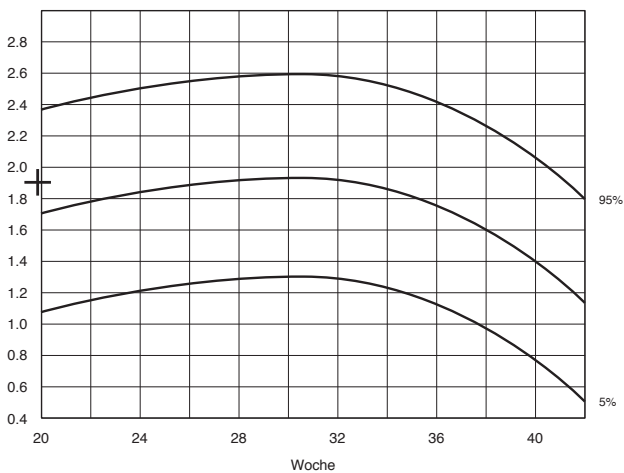
PI A. uterina links



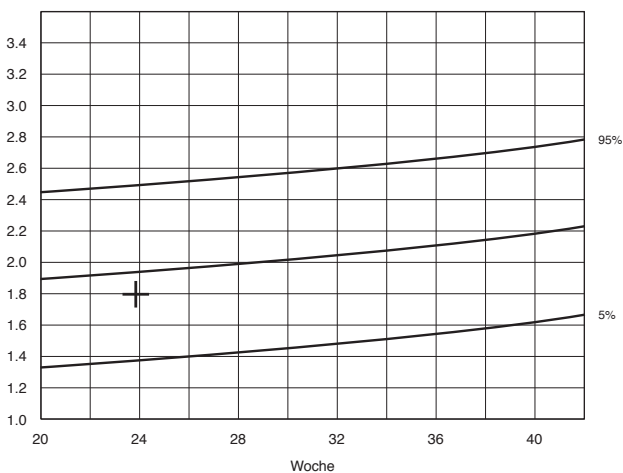
PI A. umbilicalis



PI A. cerebri media



PI Aorta fetalis



DV PIV

