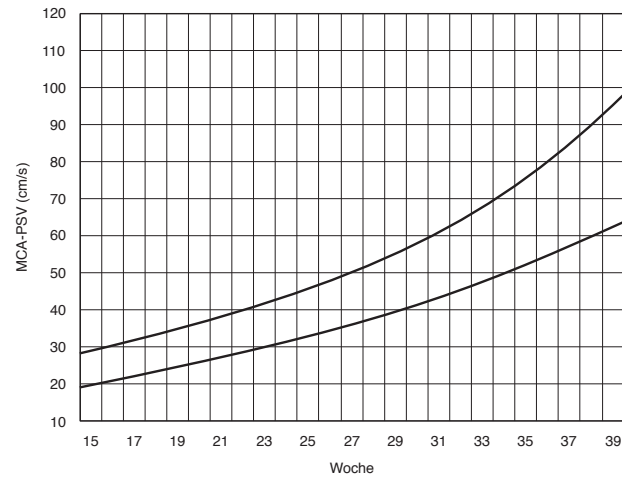


## Arteria cerebri media



Peak velocity of systolic blood flow in the middle cerebral artery (MCA) with advancing gestation. The curves indicate the median (below) and 1.5 multiples of the median (MoM) (above) peak systolic velocity (PSV) in the MCA. (Source: G. Mari et al. *The New England Journal of Medicine* 2000; 342: 9-14<sup>1</sup>.)